



# APPROACH TO OBSTRUCTIVE JAUNDICE

Yeo Quan You

# OUTLINE

- Definition of Jaundice
- Anatomy
- Causes
- Investigations
- Management
- Q & A



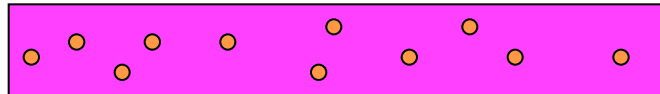

# DEFINITION OF JAUNDICE

- Jaundice is a yellowish pigmentation of the skin, the conjunctival membranes over the sclerae and other mucous membranes caused by hyperbilirubinemia and subsequently increased levels of bilirubin in extracellular fluids.
- Concentration higher than approx. 3 mg/dL ( $>50\mu\text{mol/L}$ ) leads to jaundice



# TYPES

PREHEPATIC

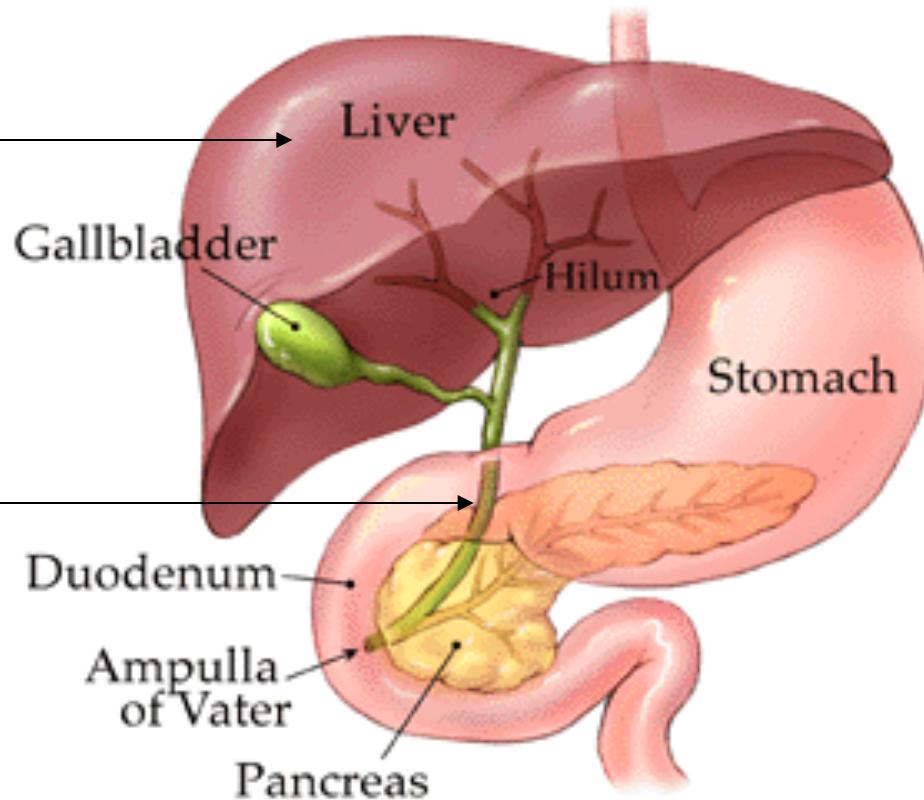


HEMOLYSIS

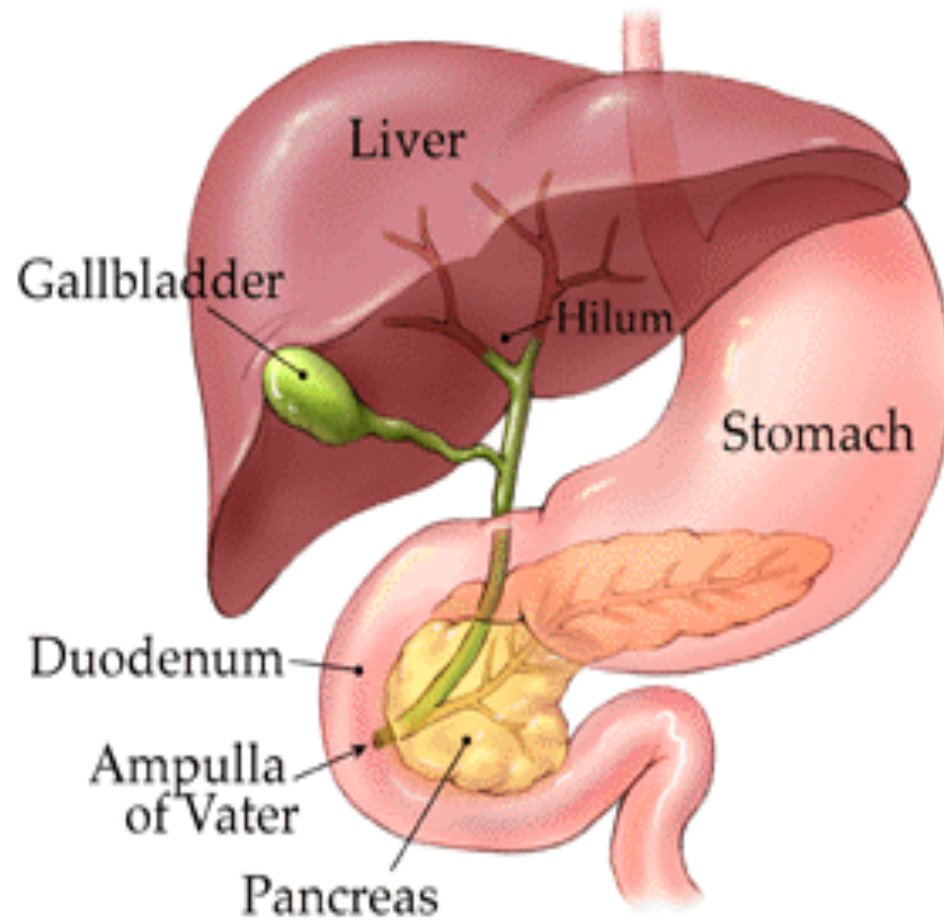
HEPATIC

POSTHEPATIC

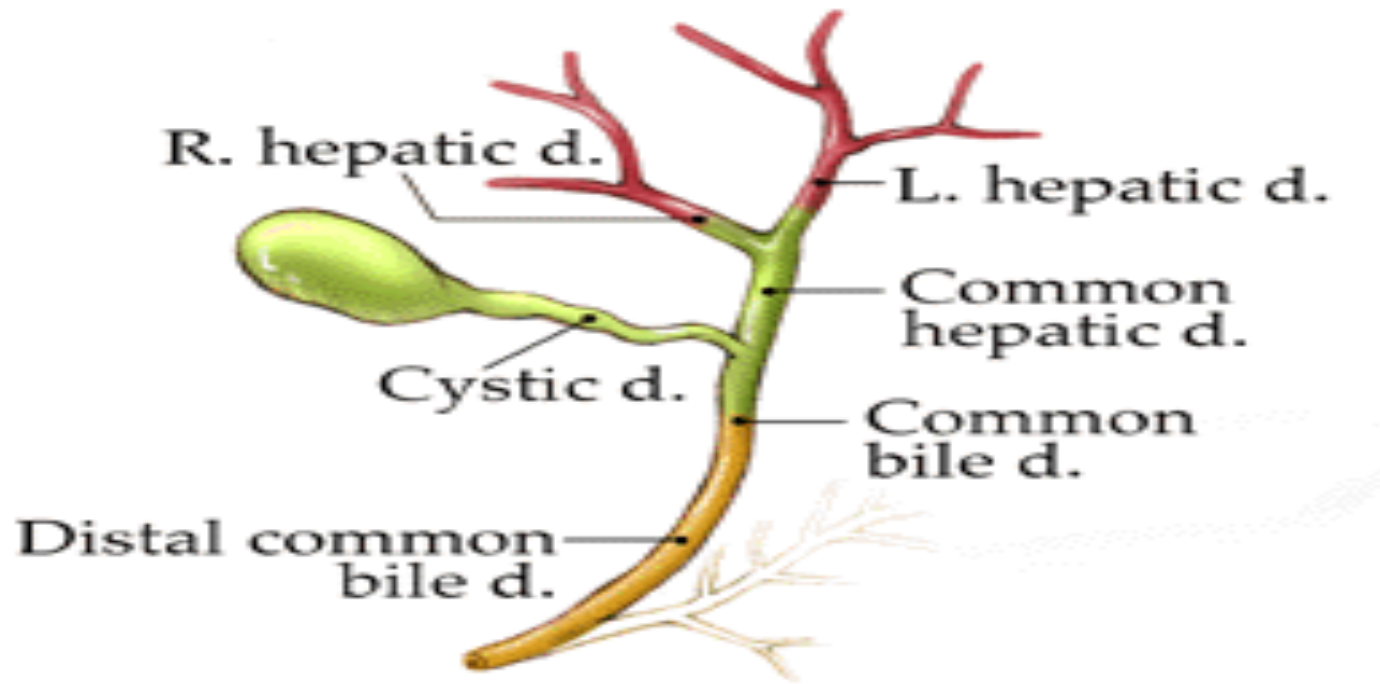
Obstructive or surgical



# ANATOMY



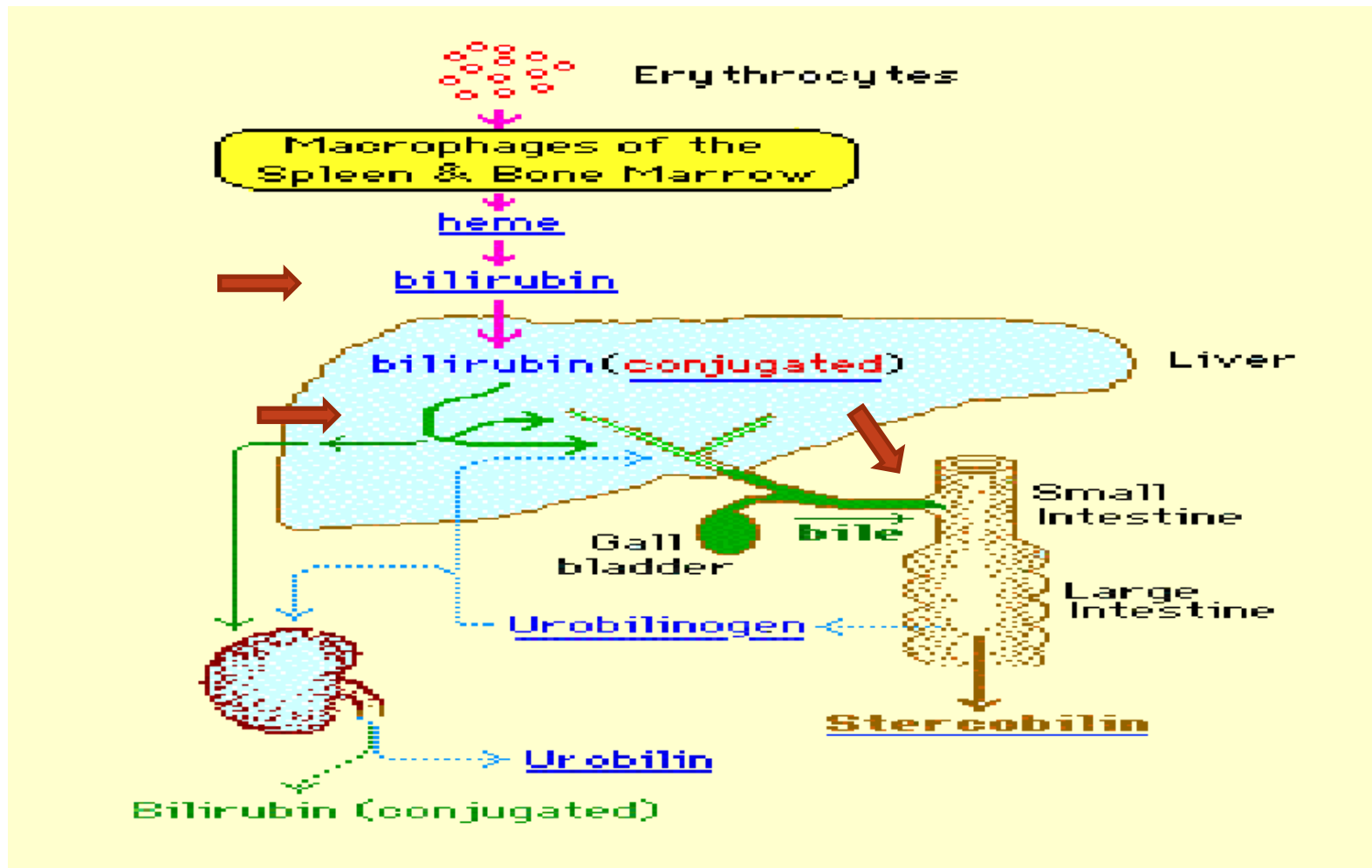
# ANATOMY



- Intrahepatic -in the liver
- Perihilar -near the hilum (where the bile ducts exit the liver)
- Distal Extrahepatic- outside the liver



# BILIRUBIN CYCLE



- Heme oxygenase oxidises heme to biliverdin.
- Biliverdin is reduced by biliverdin reductase to form bilirubin.
- Bilirubin is conjugated with glucuronic acid to form bilirubin diglucuronide, or conjugated (direct-reacting) bilirubin. This reaction, catalyzed by the microsomal enzyme glucuronyl transferase, renders the bilirubin water-soluble.





# CAUSES OF JAUNDICE

## Prehepatic:

- **Any cause of increase hemoglobin breakdown** (congenital and acquired forms of hemolysis)

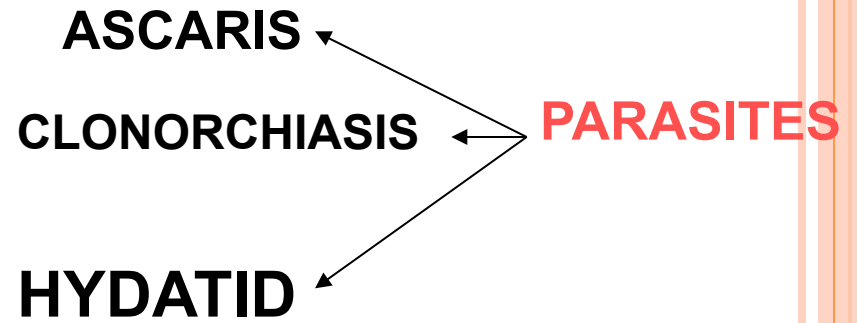

## Hepatic:

- **Congenital abnormalities of hemoglobin** metabolism (eg, Gilbert disease), conditions causing liver cell (hepatocyte) swelling or death (eg, chemical (toxic), viral, autoimmune), replacement of normal tissue by tumor/space-occupying lesions

## Posthepatic:

- **Mechanical obstruction to bile flow**, including biliary stones and strictures (benign and malignant), biliary parasites, biliary varices, chronic pancreatitis (incl autoimmune), inflammatory pseudotumor

# CAUSES IN THE LUNEN



STONE IS THE  
COMMONEST



# IN THE WALL:

## **BENIGN STRICTURES**


Post instrumentation

Primary sclerosing cholangitis

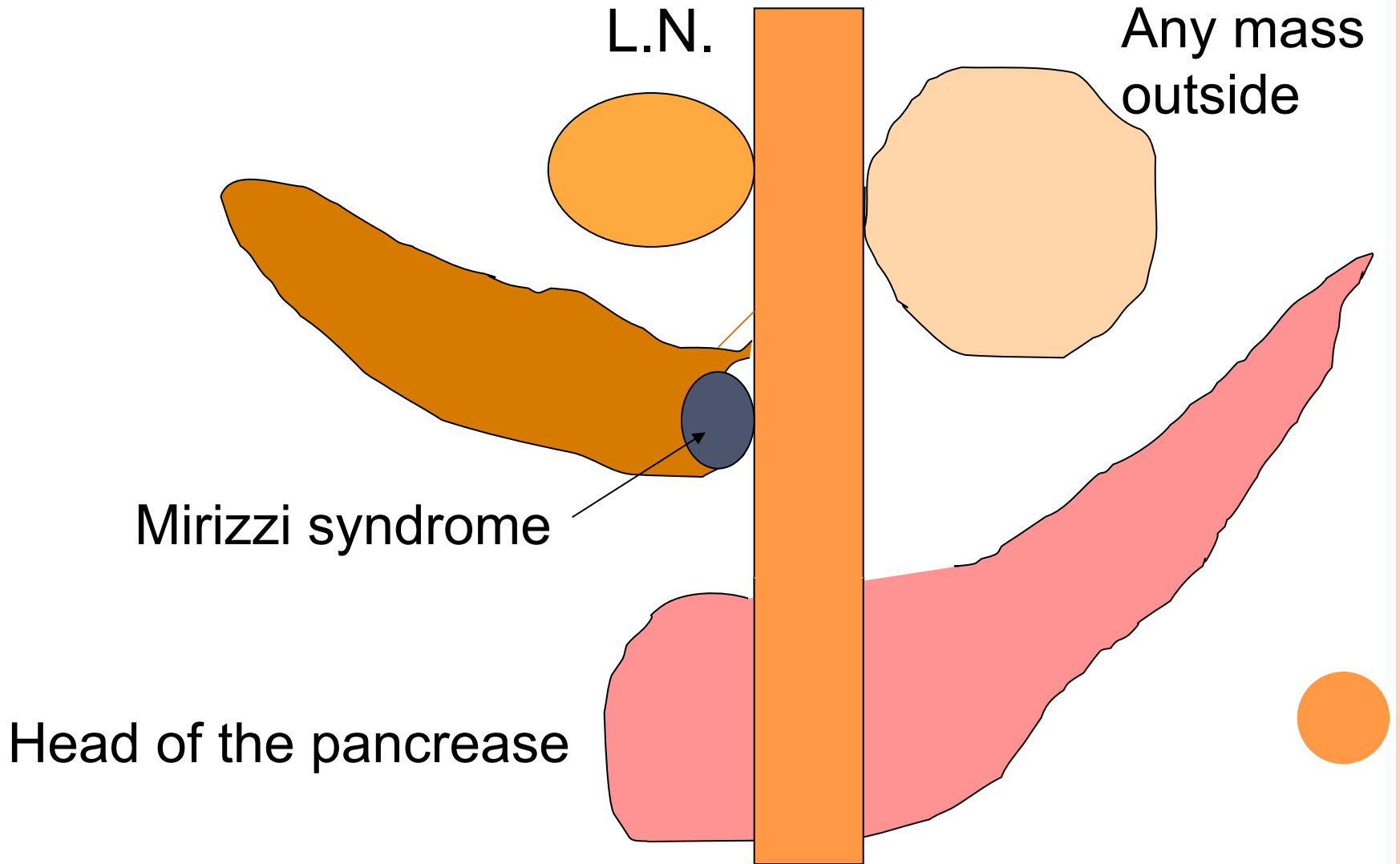
Choledochal cyst

## **MALIGNANCY**

Cholangiocarcinoma



# OUTSIDE THE WALL



# EVALUATION

- History
- Examination
- Investigations



# HISTORY

## 1. Confirm obstructive jaundice.

- Tea coloured urine and pale stools. Sclera are yellow

## 2. Aetiology

- Age- Young vs elderly.
- Pain characteristic
- Previous history of gallstone disease or biliary colic sym
- Previous history of surgery or procedure eg ERCP
- Constitutional sym- LOA LOW malaise
- Travel history

## 3. Complications

- Cholangitis
- Fat malabsorption (A,D,E,K)- eg coagulopathy
- Pruritis
- Liver compensation- encephalopathy
- Metastatic sym- bone pain, neck lump dyspnoea



# CLINICAL EXAMINATION

- Jaundice
- Pallor- hemolysis, cancer , cirrhosis
- Gross weight loss-malignancy
- Stigmata of chronic liver disease
- Supraclavicular lymph nodes
- DRE- pale stools



# ABDOMINAL EXAMINATION

- Abdominal scar
- Ascitis-Cirrhosis or malignant disease
- Hepatomegaly
- Enlarged gall bladder
  
- **Courvoisier's Law**-palpable non tender gall bladder in a jaundice patient>malignant biliary obstruction
  - Exceptions
    - Double impaction of stones
    - Impaction of pancreatic calculus at ampulla of vater
    - Mirizzi syndrome
    - Oriental cholangiohepatitis





# LABAROTORY STUDIES

- FBC: anemia, infection, Hgbpathy
- Serum U/E/Cr
- LFT
- Coagulation profile
- Tumor markers: CA 19-9
- Urinalysis : bilirubin, urobilinogen
- Stool for ocult blood: ca ampula
- Stool microscopy for ova and parasites



Table 24.2. Evaluation of liver function tests in jaundice.

Test	Source	Pattern in gallstone obstruction of the biliary tree	Pattern in acute hepatitis
Total bilirubin	Red blood cell destruction, hepatocyte processing	Elevated, but typically less than 10mg/dL	Elevated
Direct bilirubin	Conjugation by hepatocytes	Elevated	Mildly elevated
Indirect bilirubin	Red blood cell turnover, hepatocyte processing	Minimally elevated	Elevated
Alkaline phosphatase	Biliary epithelial cells and bone	Elevated	Minimally elevated
Transaminases	Hepatocytes	Minimally elevated	Markedly elevated
Gamma- glutamyl transferase	Biliary epithelial cells	Elevated	Minimally elevated



# INVESTIGATIONS (URINE)

Types of jaundice	Pre hepatic	Hepatic	Post hepatic
Type of bilirubin elevated	unconjugated bilirubin	Both conjugated & unconjugated bilirubin	conjugated bilirubin
Serum bilirubin - Van den Bergh test	Indirect positive	Biphasic	Direct positive
Urine ✓ Conj. Bilirubin ✓ Urobilinogen	Absent +++	++ + early, obst. -dec.	+++ Absent
Urine color	Normal-Acholuric	Dark - Choluric	Dark - Choluric
Stool color	Dark brown colour	N /decreased	Clay colored stools



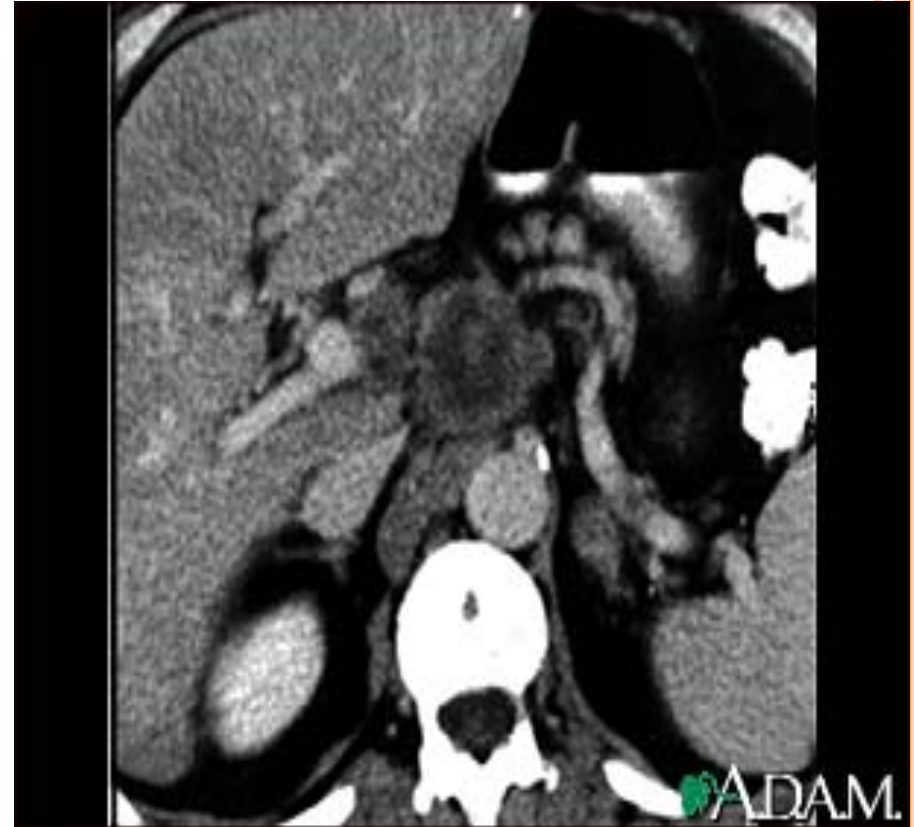# INVESTIGATION (IMAGING & PROCEDURE)

- U/S HBS
  - Stones, CBD diameter
  - More sensitive than CT to pick up stones and gallbladder pathology
- CT abdomen
- ERCP/MRCP
- EUS
- Percutaneous transhepatic cholangiogram



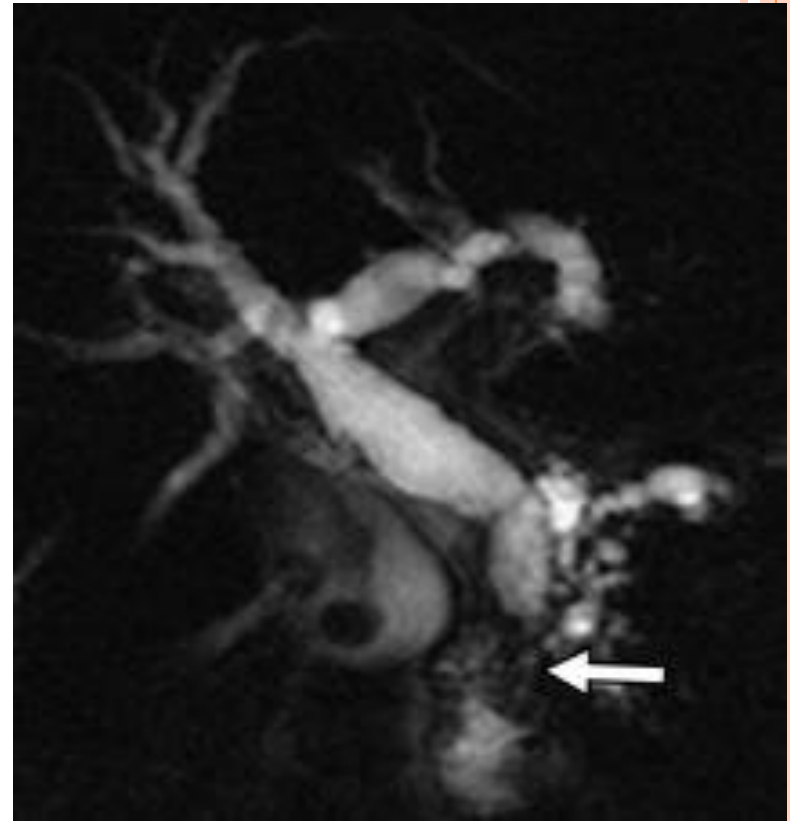
# CT scan

- Main role in malignant conditions mainly for localization of primary tumors and mets
- Best for Pancreatic Carcinoma (Highly sensitive for lesion >1mm)
- Identify level and cause of obstruction



# MAGNETIC RESONANCE CHOLANGIOPANCREATOGRAPHY (MRCP)

- Noninvasive test to visualize the hepatobiliary tree
- Entire biliary tree and pancreatic duct can be seen
- Best for intra hepatic stones and choledochal cyst
- MRCP is better to determine the extent and type of tumor as compared to ERCP



# Endoscopic retrograde cholangiogram (ERCP)

- Invasive procedure
- Direct visualization of biliary tree/ pancreatic duct
- ERCP preferred as both therapeutic and diagnostic
- Allows biopsy or brush cytology
- Stone extraction, stenting, sphincterotomy

Endoscopic Retrograde Cholangiopancreatography (ERCP)

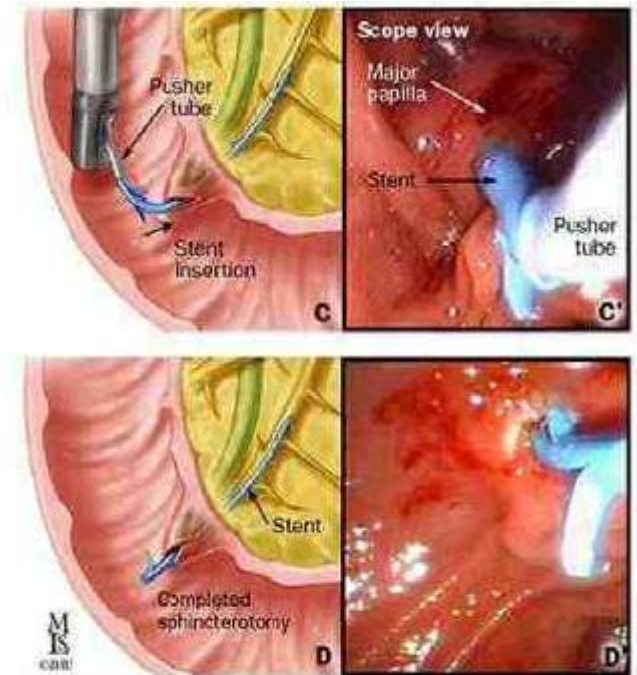
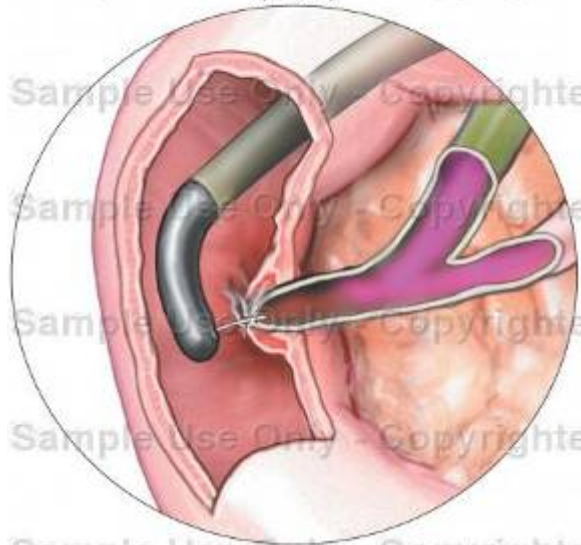


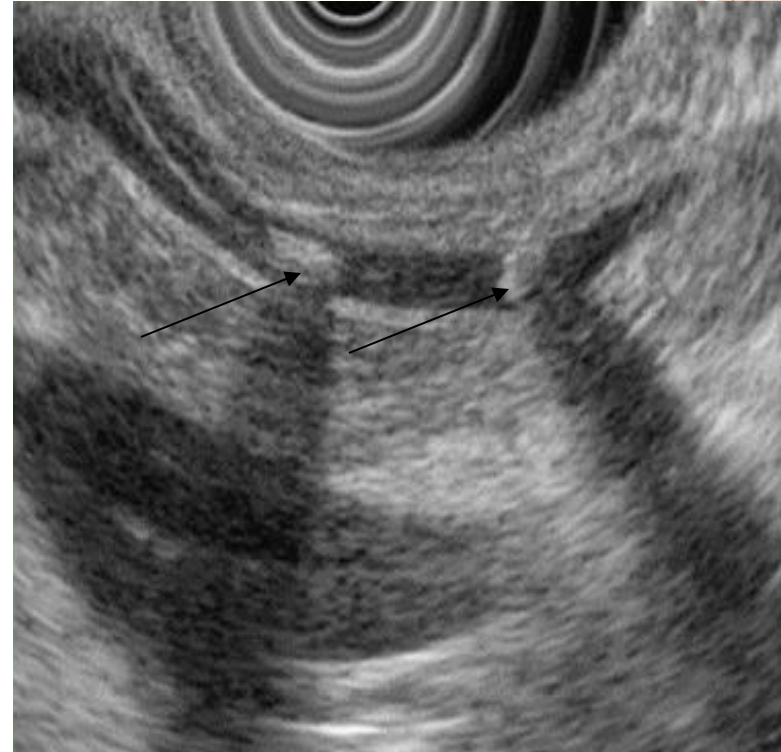Figure 19. Major papilla sphincterotomy and stent placement (A-D). A'-D', endoscopic view.





# ENDOSCOPIC ULTRASOUND (EUS)

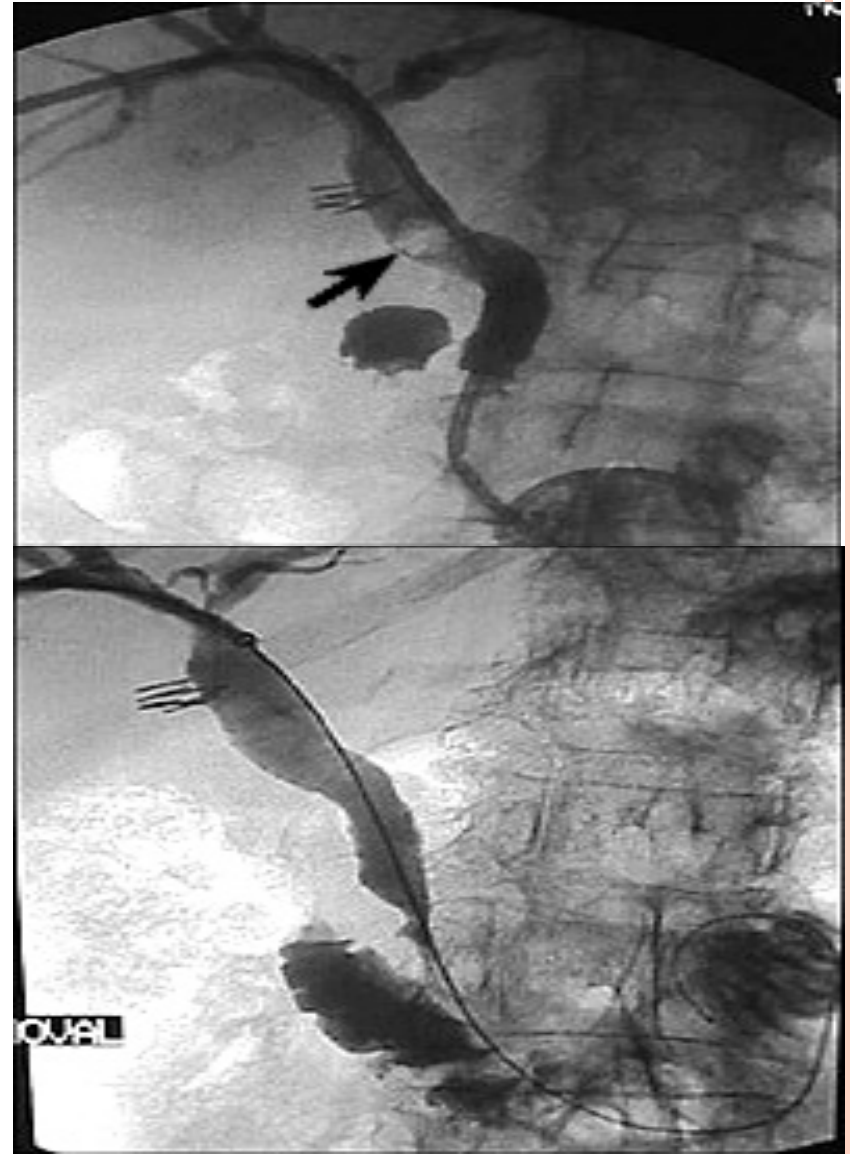
- EUS has been reported to have up to a 98% diagnostic accuracy in patients with obstructive jaundice
- Allows diagnostic tissue sampling via EUS guided fine-needle aspiration (EUS-FNA)
- The sensitivity of EUS for the identification of focal mass lesions in pancreas has been reported to be superior to that of CT scanning
- Compared to MRCP for the diagnosis of biliary stricture, EUS has been reported to be more specific (100% vs 76%)





# Percutaneous Transhepatic Cholangiogram (PTC)

- Maybe useful for obstruction proximal to CHD
- PTC is indicated when percutaneous intervention is needed and ERCP either is inappropriate or has failed.
- Can be used to drain biliary obstructions.



# Management

## Perioperative management of obstructive jaundice

- Preoperative biliary decompression improves postoperative morbidity
  - usually cause increased hemorrhage & infections
  - Indicated in severe jaundice or when there are signs of severe sepsis
- Bladder catheterization to monitor output
- Broad spectrum antibiotic prophylaxis if cholangitis
- Parenteral vitamin K +/- fresh frozen plasma if coagulopathy
- Need careful post operative fluid balance to correct dehydration
- Antihistamine for symptomatic relief of pruritus



# Treatment of Obstructive Jaundice is based on the cause

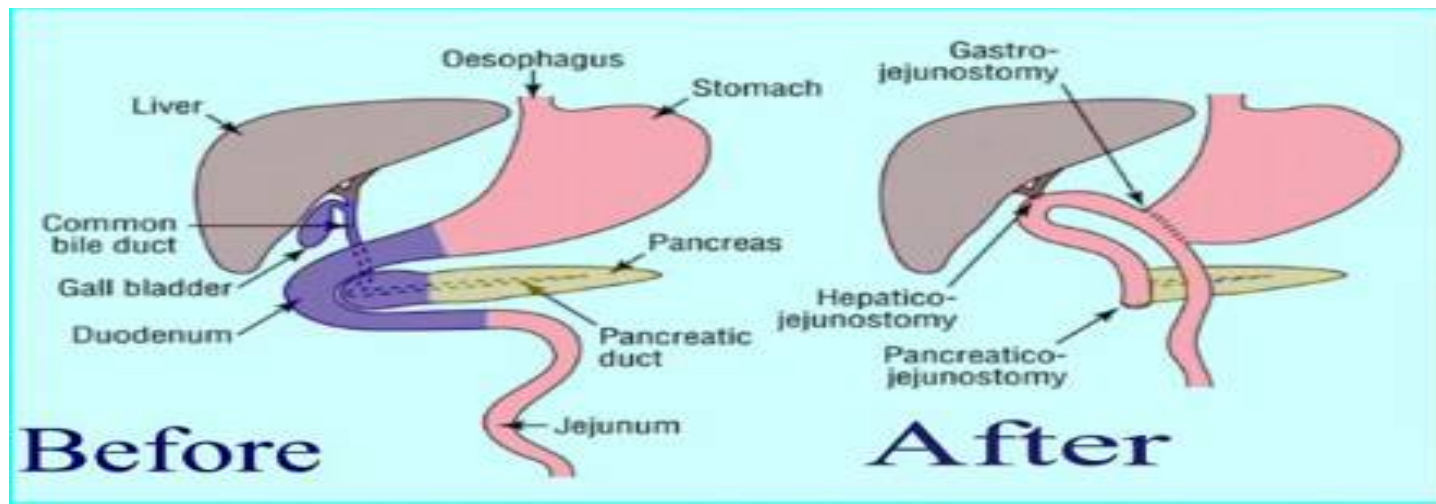
## 1) Choledocholithiasis (gallstones)

- a) Treatment of choice is stone extraction through ERCP
- b) Mechanical lithotripsy – through modified dormia basket
- c) Open exploration of common bile duct is indicated in
  - Presence of multiple stones or > 25mm
  - Intra hepatic stones
  - Failure of ERCP
  - Recurrence of CBD stones



## 2) Ca Head of Pancreas / Periapillary Carcinoma/malignancy of lower 3<sup>rd</sup> of CBD

- a) Whipple resection (pancreaticoduodenectomy) is mainly done which involves removal of head & neck of pancreas, duodenum, distal 40% of stomach, lower CBD, GB, upper 10 cm of jejunum, regional L.Ns and reconstruction through gastrojejunostomy, choledochojejunostomy and pancreaticojejunostomy
- b) If not operable then we go for Endoscopic sphincterotomy + stenting or Percutaneous transhepatic biliary drainage



### 3) Cholangiocarcinoma

Surgery depends on the stage of tumor and may involve

- Removal of the bile ducts  
If the tumor is at a very early stage (Stage 1), just the bile ducts containing the cancer are removed. The remaining ducts in the liver are then joined to the small bowel, allowing the bile to flow again.
- Whipple procedure  
If the tumor is larger and has spread into nearby structures, the bile ducts, part of the stomach, part of the small bowel (duodenum), the pancreas, gall bladder and the surrounding lymph nodes are all removed
- If surgery to remove the tumour is not possible, it may be possible to relieve the blockage through stents through ERCP or PTC



## 4) STRICTURES

- usually treated by endoscopic stenting which is comparable to that of surgery, with similar recurrence rates.
- Therefore, surgery should be reserved for those patients with complete ductal obstruction or for those in whom endoscopic therapy has failed.



# Questions 1

In obstructive jaundice, urinary examination shows:

- A) No urobilinogen, no bilirubin
- B) Increased urobilinogen, increased bilirubin
- C) Increased urobilinogen, no bilirubin
- D) No urobilinogen, increased bilirubin



# ANSWER 1 (D)

Types of jaundice	Pre hepatic	Hepatic	Post hepatic
Type of bilirubin elevated	unconjugated bilirubin	Both conjugated & unconjugated bilirubin	conjugated bilirubin
Serum bilirubin - Van den Bergh test	Indirect positive	Biphasic	Direct positive
Urine ✓ Conj. Bilirubin ✓ Urobilinogen	Absent +++	++ + early, obst. -dec.	+++ Absent
Urine color	Normal-Acholuric	Dark - Choluric	Dark - Choluric
Stool color	Dark brown colour	N /decreased	Clay colored stools





## QUESTIONS 2

---

A 62-year-old man with inflammatory bowel disease was diagnosed with primary sclerosing cholangitis 5 years ago. He now presents with weight loss and a more rapid deterioration of his liver function. On examination he is cachectic, liver function tests reveal a profoundly obstructive picture with raised bilirubin, gamma-glutamyltransferase and alkaline phosphatase levels, accompanied by a lesser increase in alanine aminotransferase (ALT). There is nothing to suggest an acute infective process.

Which diagnosis fits best with this clinical picture?

- Hepatocellular carcinoma
- Primary carcinoma of the gallbladder
- Cholangiocarcinoma
- Ascending cholangitis
- Primary biliary cirrhosis



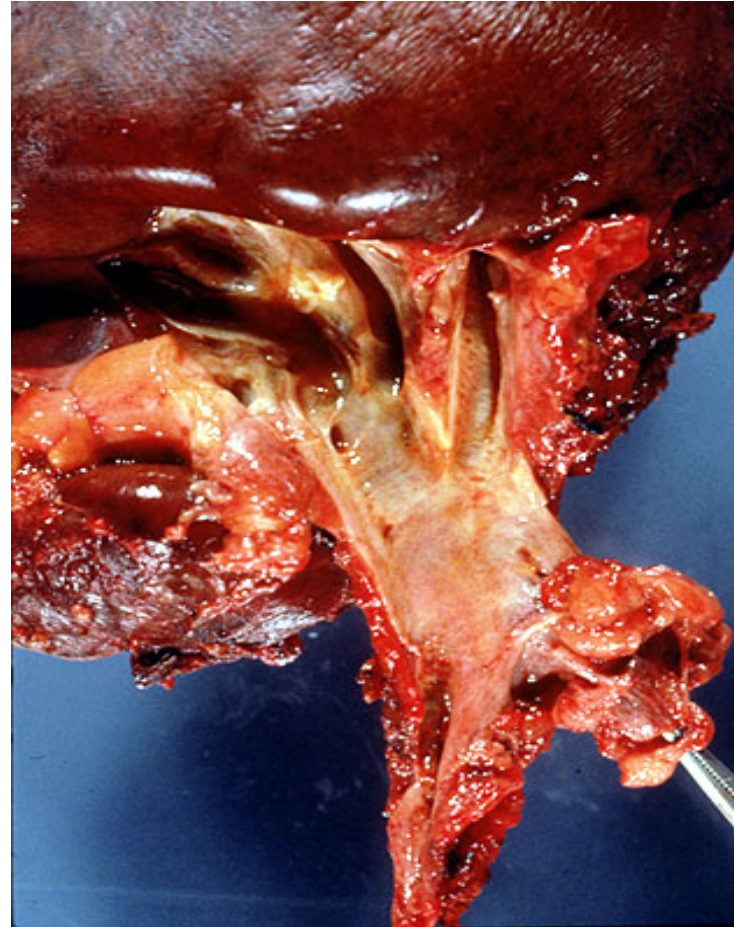
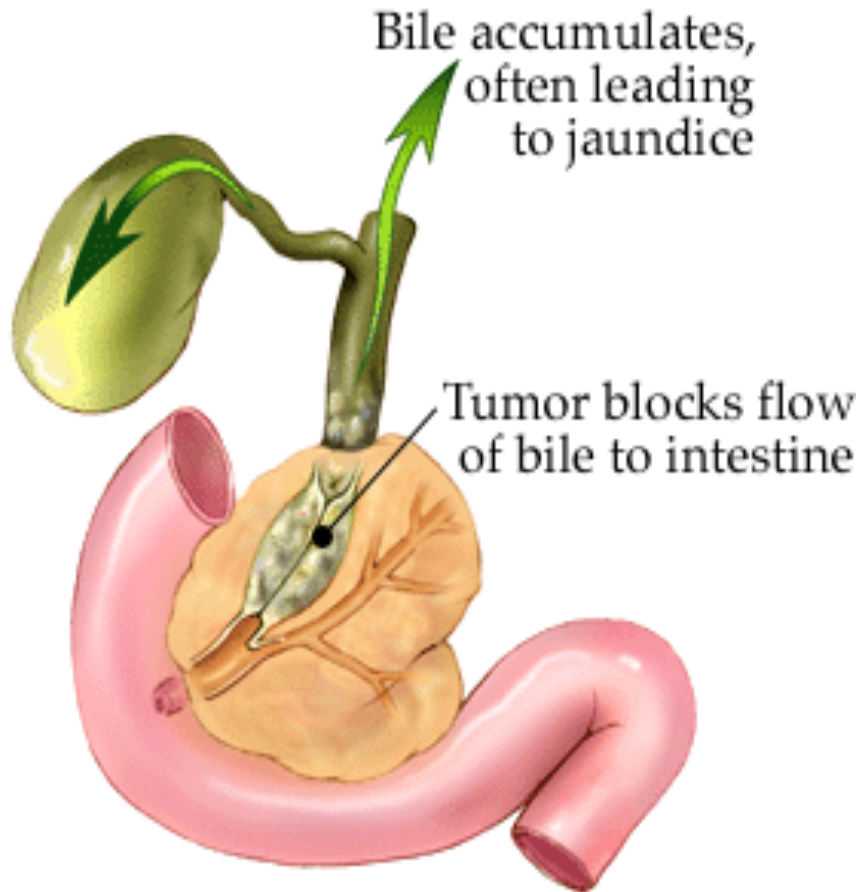
## ANSWER 2

### Cholangiocarcinoma

Cholangiocarcinoma has a well-recognised association with primary sclerosing cholangitis. It can also occur in association with a choledochal cyst and chronic infection of the biliary tree. Patients usually present with rapidly worsening jaundice. The diagnosis can usually be made with a combination of ultrasound and spiral computed tomography or magnetic resonance cholangiopancreatography (MRCP). Proximal lesions are usually not readily resectable at presentation because of local spread. Patients can, however, usually be offered palliation with metal stenting to maintain patency of the bile duct.



# CHOLANGICARCINOMA



## QUESTION 3

A 50-year-old woman presents with a 1-year history of recurrent episodes of right upper abdominal pain. She has now had jaundice and fever for the past 4 days. On examination she appears toxic. Her blood pressure is 90/60 mmHg. Abdominal ultrasonography demonstrates stones in the common bile duct.

What is the best next step once she is adequately stabilised?

- Endoscopic bile duct stone extraction
- Laparoscopic cholecystectomy
- Laparotomy and stone extraction
- Lithotripsy
- Open cholecystectomy



# ANSWER 3

## A) ERCP

### Acute cholangitis

This patient has cholangitis presenting as **Charcot's triad** – fever, pain and jaundice. She is also toxic. The definitive management is to relieve the pressure in the obstructed biliary system. **Endoscopic bile duct clearance** is the preferred technique. Cholecystectomy is indicated in symptomatic gallstones but if possible not in the stage of acute cholecystitis.

Extracorporeal shock-wave lithotripsy (ESWL) might not be useful in this case because the stones have to be evaluated for size and composition – the greater the calcium content of the stone, the less likely the success of fragmentation. The stones also have to be greater than 10 mm in diameter; common bile duct stones can be smaller than this.





## QUESTION 4

A 45-year-old woman with ulcerative colitis is admitted with a history of jaundice, pruritus and intermittent abdominal pain. Examination shows hepatosplenomegaly and mild ascites. Blood tests confirm an obstructive jaundice, and anti-mitochondrial antibodies are not detected.

What is the most likely diagnosis?

- Liver cirrhosis
- Chronic active hepatitis
- Sclerosing cholangitis
- Metastatic carcinoma
- Pancreatic carcinoma



# ANSWER 4

## Sclerosing cholangitis

This patient has inflammatory bowel disease and is at risk of developing sclerosing cholangitis. This results from inflammation and fibrosis of the bile ducts, which leads to the formation of multiple areas of narrowing throughout the biliary system. Patients with acquired immune deficiency syndrome also develop sclerosing cholangitis.

### *Clinical features*

Patients can be asymptomatic or can present with jaundice, pruritus and intermittent abdominal pain. The alkaline phosphatase level will be raised and the mitochondrial antibody is not detectable. Liver biopsy will show fibrous obliterative cholangitis with loss of interlobular and adjacent septal bile ducts. Endoscopic retrograde cholangiopancreatography (ERCP) will demonstrate the multiple strictures. Treatment is unsatisfactory – methotrexate has been used, but liver transplantation may be needed.



